

**MINISTRY OF EDUCATION AND SCIENCE OF THE RUSSIAN FEDERATION**

**Federal public educational budgetary institution education**

**Ulyanovsk state university**

**INSTITUTE OF MEDICINE, ECOLOGY AND PHYSICAL CULTURE**

**Medical faculty of T.Z.Biktimirov**

**DEPARTMENT OF THE GENERAL AND OPERATIONAL SURGERY**

**WITH TOPOGRAPHICAL ANATOMY AND COURSE OF STOMATOLOGY**

**A.V. Smolkina, S.V. Makarov,**

**V.P. Demin, S.I. Barbashin**

**Sharp purulent diseases of skin and  
hypodermic fatty cellulose**

**Study Guide (e-course)**

Ulyanovsk, 2019

UDC 617-089.168.1-083:616-083.98 (075.8)  
BBK 54.53ya73+53.50ya73  
To 44

Published according to the decision of the Academic Council  
Institute of Medicine, Ecology and Physical Culture  
(Protocol No. 8/208 of 10 April 2019)

**Reviewers:** doctor of medical sciences, professor Yuri Grigorievich Shapkin

**Author's collective:**

**Smolkina Antonina Vasilievna** - MD, associate professor, head of the Department of General and Operative Surgery with topographic anatomy and a course of dentistry of the State Pedagogical University of Ulyanovsk State University of the Ministry of Education and Science of the Russian Federation.

**Makarov Sergey Victorovich** - Candidate of Medical Science, associate professor of the Department of General and Operative Surgery with topographic anatomy and a course of dentistry of the State Pedagogical University of Ulyanovsk State University of the Ministry of Education and Science of the Russian Federation.

**Demin Vladimir Petrovich** - Candidate of Medical Science, associate professor of the Department of General and Operative Surgery with topographic anatomy and a course of dentistry of the State Pedagogical University of Ulyanovsk State University of the Ministry of Education and Science of the Russian Federation.

**Barbashin Sergey Ivanovich** - Candidate of Medical Science, associate Professor at the Department of Hospital Surgery, Anesthesiology, Resuscitation, Urology, Traumatology and Orthopedics of the State Pedagogical University of Ulyanovsk State University of the Ministry of Education and Science of the Russian Federation.

Sharp purulent diseases of skin and hypodermic fatty cellulose – science about bandages / Smolkina A. V., Makarov S.V., Demin V.P., Barbashin S.I. - Ulyanovsk, 2019. - 21 p.

The educational and methodological manual summarizes the literature data and long-term research of the collective of the department of general and operative surgery with topographic anatomy and the course of stomatology of the Institute of Medicine, Ecology and Physical Culture, Ulyanovsk State University. The manual presents the main diseases of purulent infection.

The educational-methodical manual is intended for students of medical universities, clinical residents, surgeons, traumatologists, family practice doctors.

@ Team of authors, 2019

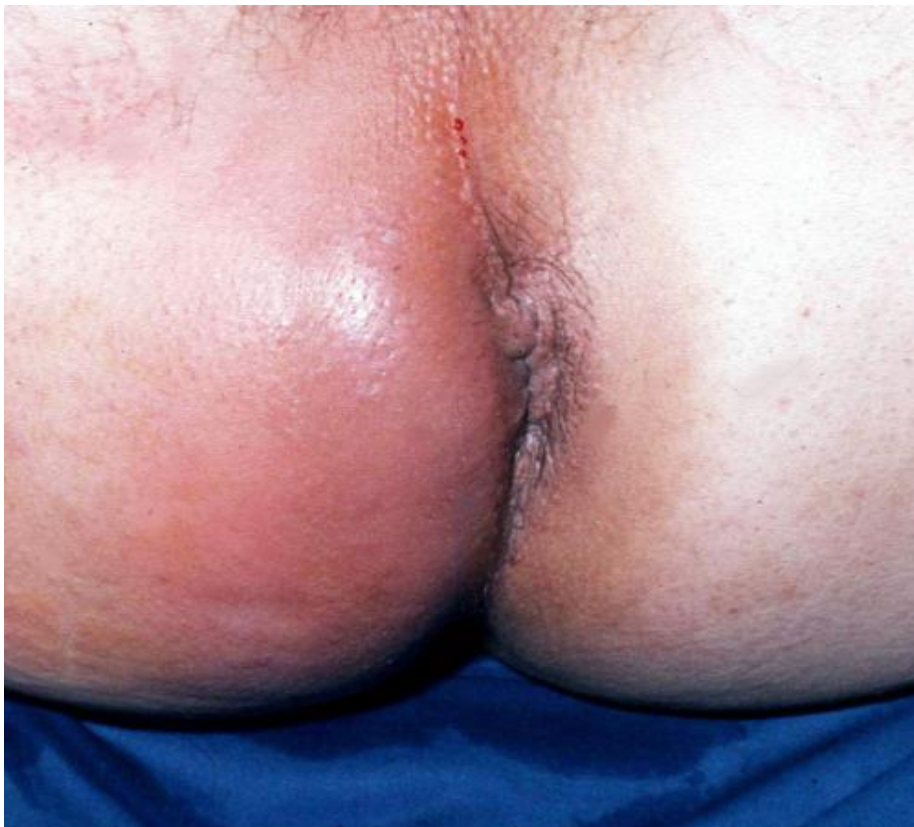@ Ulyanovsk State University, 2019

## **General information of purulent diseases**

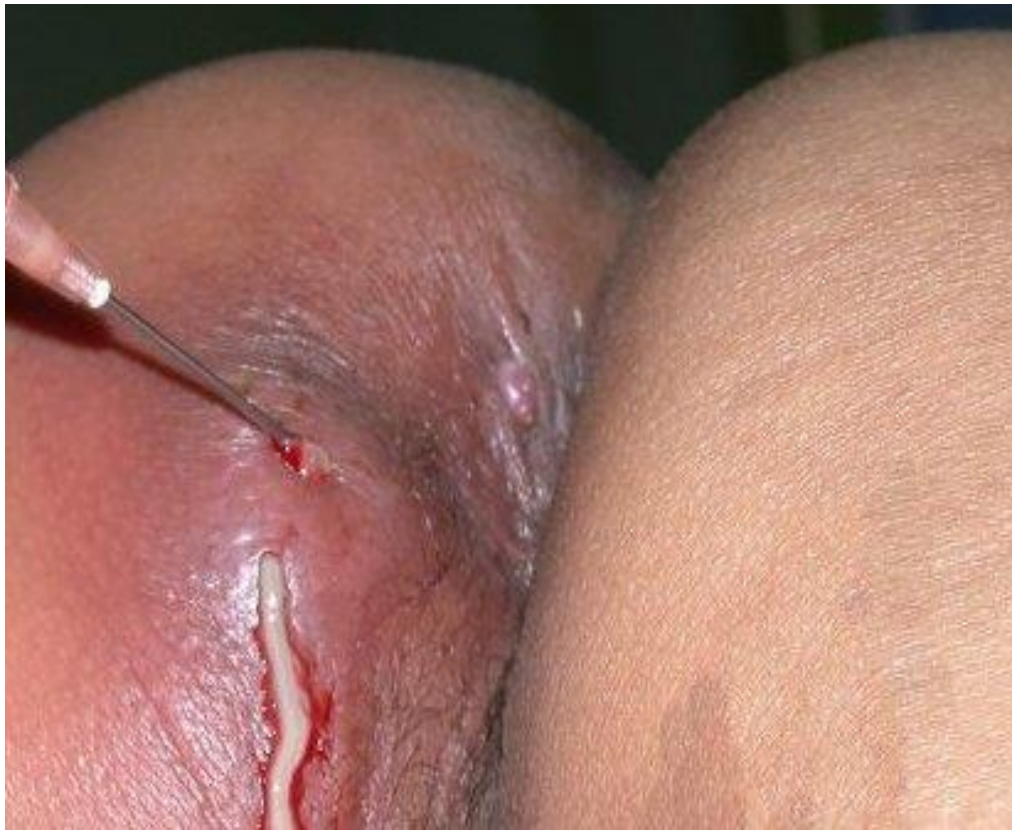These diseases are among the most common, both in the inpatient and outpatient practice. For their appearance must have general and local promoting disease factors. General factors - factors that weaken the reactivity (stress, vitamin deficiency, diabetes, eating disorders, and others.). Local factors - the entrance gate, the presence of pathogens and nutrient medium for bacteria (exudate, blood, dead tissue, and others.).

Morphologically, the local process in its flow has the following steps:

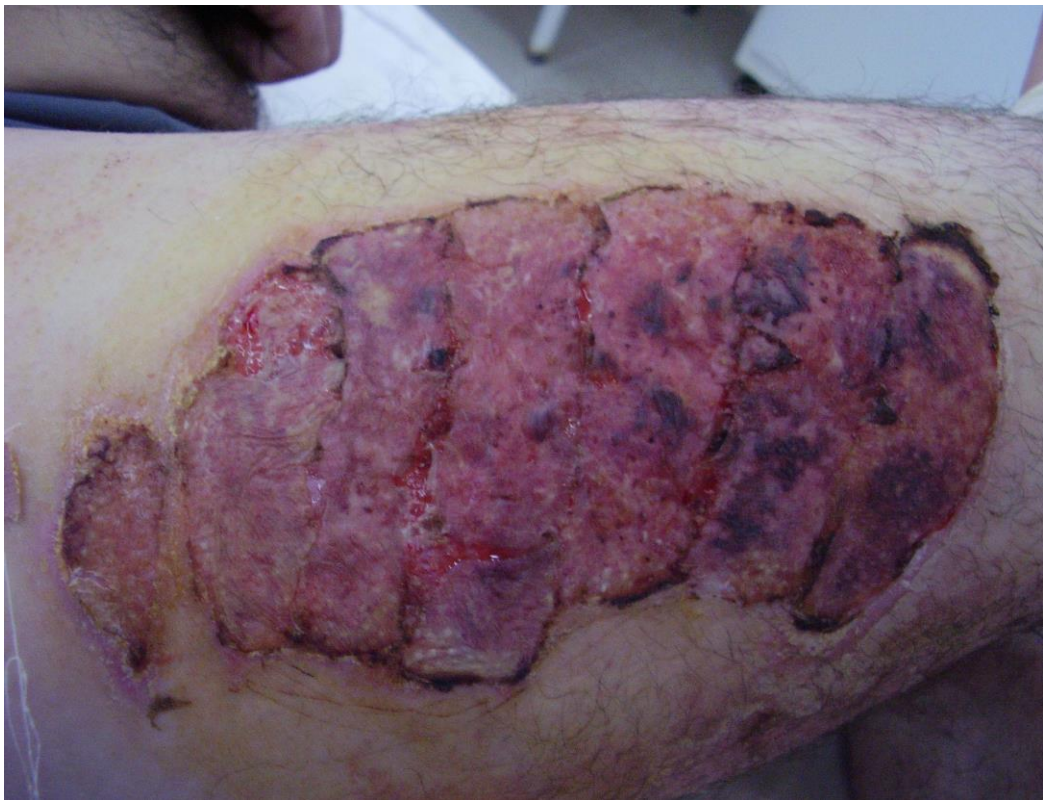1. serous-infiltrative ( Fig.1 ) ;
2. abscess (abscess cavity formation) ( Fig.2);
3. The regeneration (healing) ( Fig.3).



**Fig.1. Serous-infiltrative**



**Fig.2. Abscess**

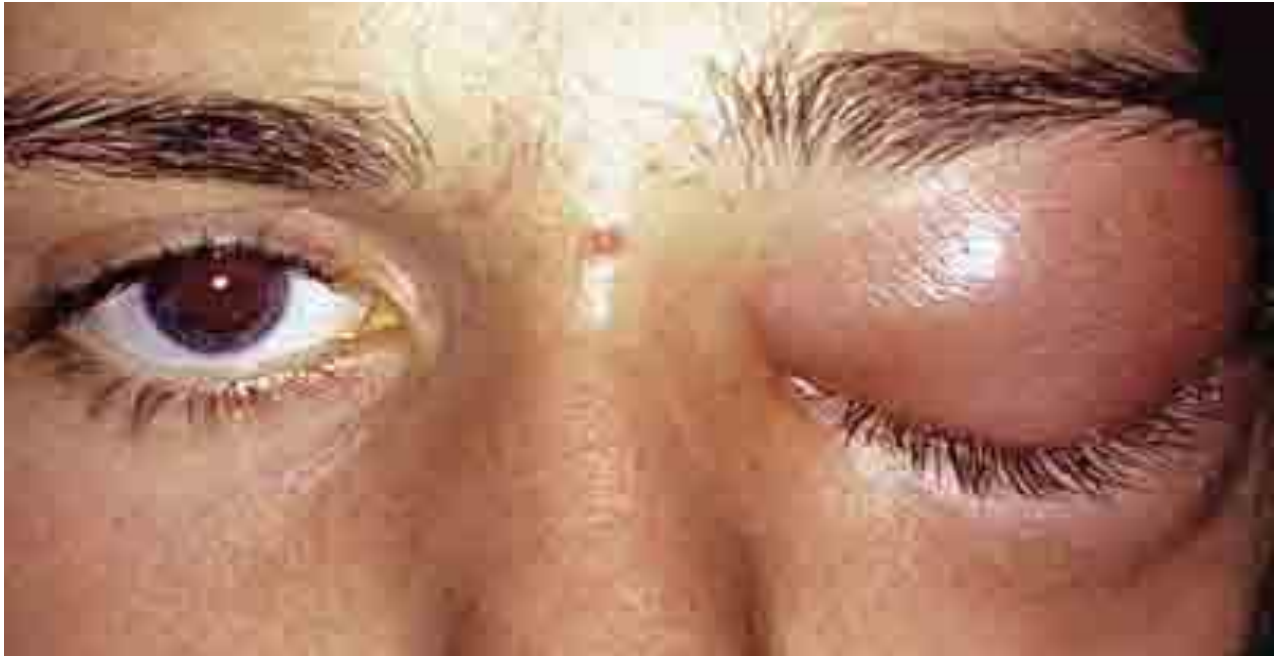

**Fig.3. The regeneration**

In the first stage to the point of introduction of bacteria replenished leukocytes and macrophages, phagocytic grasping foreign bodies and bacteria. Thus due to loss of leukocytes and bacteria phagocytosed allocated biologically active substances: proteolytic (or digesting lysosomal) enzymes, solubilizing bacteria or foreign bodies, inflammatory and proinflammatory cytokines, et al., Which contributes to a local vasodilatation, edema, exudate propotevanie (inflammatory fluid) a tissue, a local increase in temperature, pain. These effects are mainly related to the impact of lysosomal enzymes to the surrounding tissues. The decomposition products of bacteria and white blood cells with the progression of the process to form a purulent cavity with the transition to the second stage - the abscess. After opening of the cavity in the treatment of purulent process proceeds to the stage of regeneration scarring and epithelialization.

In the development of inflammatory processes, wherever they are localized around the center of the implementation of infection the body forms evolved in the evolution of protective mechanisms prevent the spread of infection. So in the first phase of the inflammatory focus and location of bacteria surrounded by leukocytes and macrophages, which as mentioned above phagocytose pathogens inflammation. Thus formed the first defense mechanism - leukocyte shaft. With further development of the process in its transition to the second stage begins when the formation of purulent cavity, and when inflammation around the hearth falls fibrin, which forms a protective gluing pyogenic membrane or capsule. If the ulcer was opened in this step, the capsule in place pyogenic formed granulating shaft. After opening the abscess shaft contributes to the process of healing and scarring. If a purulent lesion in the inflammatory process could not adequately drained, it further promotes the formation of a fibrous sheath that marks the formation of chronic purulent process, such as is the case with the formation of chronic osteomyelitis (bone inflammation) or chronic lung abscess. It should be noted that squeezing boils, their accidental trauma, ulcers obkalyvanie all localizations drugs contributes to a violation of the above restrictive mechanisms and can lead to the spread of the process, or even to the emergence of a common purulent infection called sepsis. Inflammatory processes of any localization

are general and local symptoms. Common symptoms - symptoms of purulent intoxication: fatigue, malaise, headache, insomnia, loss of appetite, fever. Local symptoms - it's a pain, swelling, redness, local temperature, rise dysfunction (Fig.4).



**Fig.4. So, the main thing – oedema, rubor, color, dolor, functio lease**

The purulent processes of the cellular spaces are mainly phlegmon localized in certain fascial cellulose spaces located in deep anatomical areas of the body or in cavities containing often important anatomical structures and prone to spread not only within these spaces, but also to neighboring areas and organs.

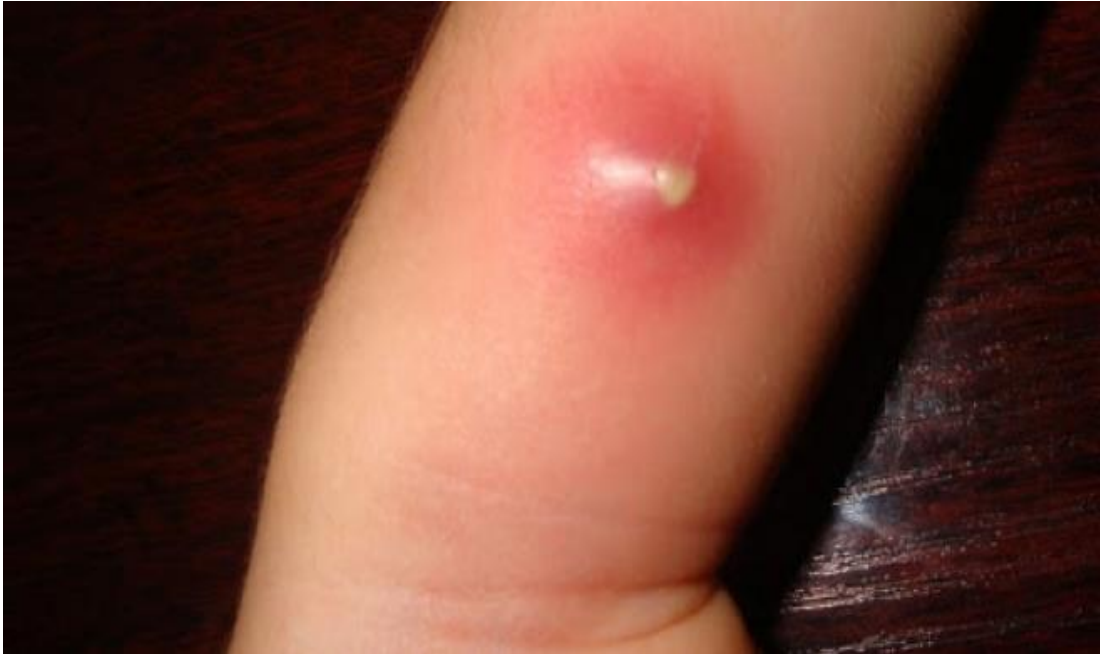These phlegmon include phlegmon of the neck, axillary and subpectoral phlegmon, deep phlegmon of the extremities, purulent mediastinitis, perinephritis, psoitis and paracolitis, acute paraproctitis.

It will be the characteristic of purulent processes of localization.



## **Boil – furuncle**

Boil (furuncle) - a necrotic inflammation of the hair follicle and the surrounding subcutaneous fat ( Fig.5 ).



**Fig.5. Furuncle**

The most common site of boils are back of the neck, upper arm, back of the hand, face, thigh. The appearance of two or more boils shows abrasions. The causative agent is *Staphylococcus aureus* boils. It should be pointed out that boils at the process involved the so-called vellus hair covers the entire surface of the body covered with epidermis, except for the red portion of the lips, palms and plantar surfaces of the rear surface of the nail phalanges of the hands and feet, the labia and the inner surface of the labia majora, foreskin, t.e.zdes too, are inflammatory processes, but it is not boils.

Contributing factors are weakening the body, metabolic disorders (mostly diabetes), beriberi, skin diseases. The process begins with the formation of pus pustules formed in the center of infiltration necrosis (necrosis, necrotic core), necrosis around the pus accumulates. Some features are facial boils, especially located above the cut line and the corners of his mouth. This feature is that the veins collect blood

from the face of the fall in the corner of the nose vein (v. Angularis nasi), which in turn flows into the ophthalmic vein. (V. Ophtalmica), which flows into the cavernous sinus is located inside the skull. Inflammation of the face can spread to the veins and can lead to thrombophlebitis (inflammation of a vein) of the cavernous sinus, brain abscess, meningitis (inflammation of the meninges). Therefore, patients with boils this localization should be treated in a hospital.

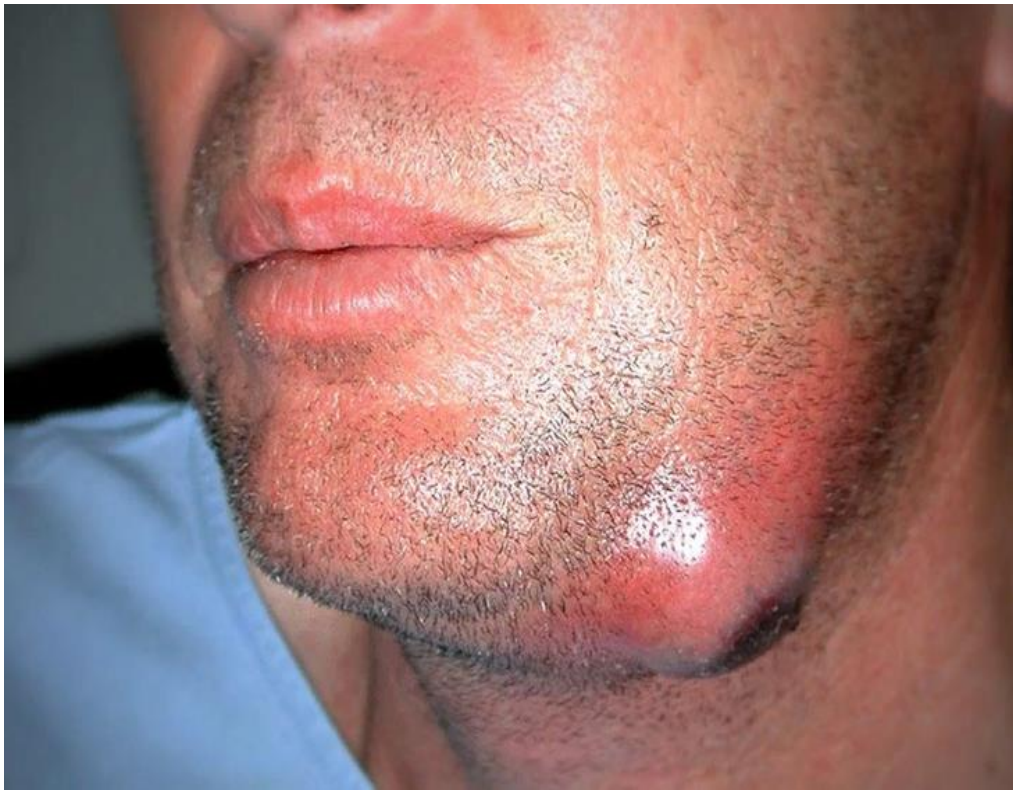Treatment. Conservative treatment of purulent inflammatory process in the sero-infiltrative phase.

In the far, during the formation of an abscess - mandatory opening and drainage of purulent cavity with the appointment of antibiotic therapy.



## **Carbuncle**

Carbuncle - an acute diffuse necrotic inflammation of several hair follicles and sebaceous glands, accompanied by the formation of infiltration and necrosis of the skin and subcutaneous tissue due to thrombosis (blockage) of blood vessels( Fig.6 ).



**Fig.6. Carbuncle**

Pathogen - Staphylococcus aureus, less streptococcus sometimes Staphylococcus and Streptococcus. Predisposing factors-is weakening the overall resistance of the organism during hypo- and beriberi, diabetes. Places localization - back of the neck, neck, upper and lower lip, back, back. The disease begins with the appearance of infiltration, covering some of the hair follicles and sebaceous glands. There circulatory disorders, formation of necrosis of the skin, subcutaneous tissue.

Opening of the abscess with cruciform access, includes wide dissection, removal of all necrotic and non-viable tissues. After the operation, a tampon with proteolytic enzymes and a hypertonic solution of sodium chloride is injected into the

wound. In the postoperative period, for the final rejection of necrotic masses and purification of the postoperative wound, daily dressings with hypertonic solution and proteolytic enzymes are carried out. In some cases, there is a need for additional staged necrotomy. The large area and depth of tissue damage in the carbuncle leads to the fact that the postoperative wound heals with the formation of a noticeable and rough scar.

Of the physiotherapeutic methods of treatment in the stage of maturation of the carbuncle and in the postoperative period, local UFO and UHF-therapy are used. If necessary, ultraviolet blood irradiation and intravenous laser blood irradiation are performed to stimulate the body's defenses. Indications for treatment in the hospital are: severe intoxication, large size of the carbuncle, its localization on the face, the presence of uncompensated diabetes and other serious diseases in the patient.

Complication. The complications arising from the carbuncle are associated with the spread of the infection deep into the tissues, along the vessels and its penetration into the blood. Usually they develop in debilitated patients or in the absence of adequate treatment.

The spread of the infection deep into the soft tissues can lead to the formation of a soft tissue abscess or the appearance of phlegmon, infection of the bone leads to the development of osteomyelitis. When the infection passes to the venous vessels, phlebitis and thrombophlebitis develop. Possible bleeding from the affected vessels. With the involvement of lymphatic vessels and nodes may occur sero-purulent lymphadenitis, lymphangitis, periadenitis and adeno-phlegmon. In some cases, there is the addition of erysipelas.

### **Hydradenitis. Abscess. Mastitis. Whitlow.**

Hydradenitis - purulent inflammation of the apocrine sweat glands. Caused by *Staphylococcus aureus*, penetrating through the excretory duct of the sweat glands. These glands secrete sweat and odor, and they are formed in the period of sexual flowering, they do not have children and less in the elderly. Localized cancer in the armpit, groin, around the nipples and perianal area. Disease contributes to: failure to comply with personal hygiene, excessive sweating, skin contamination, skin diseases (dermatitis, eczema). The sweat glands develop inflammatory infiltration of tissues with subsequent purulent fusion. On examination, often painful swelling in the armpit, at least in the groin. Disease begins acutely, with the appearance of small painful nodules that increase sharply above the surface of the skin. On examination, the swelling is marked purple-red color. With involvement of the sweat glands of several nodes are merged into a dense infiltration, which may take all of the axilla. After 10-15 days of selection begins creamy pus. After a discharge of pus from the wound comes scar formation.

Abscess - collection of pus in a limited variety of tissues and organs, not prone to the spread due to the presence of the capsule. Abscess - a special form of purulent surgical infection, which can develop into various tissues and organs. The cause - tissue penetration pyogenic bacteria through scrapes, injections, wound. The difference between abscess and infiltration is the presence of fluctuation.

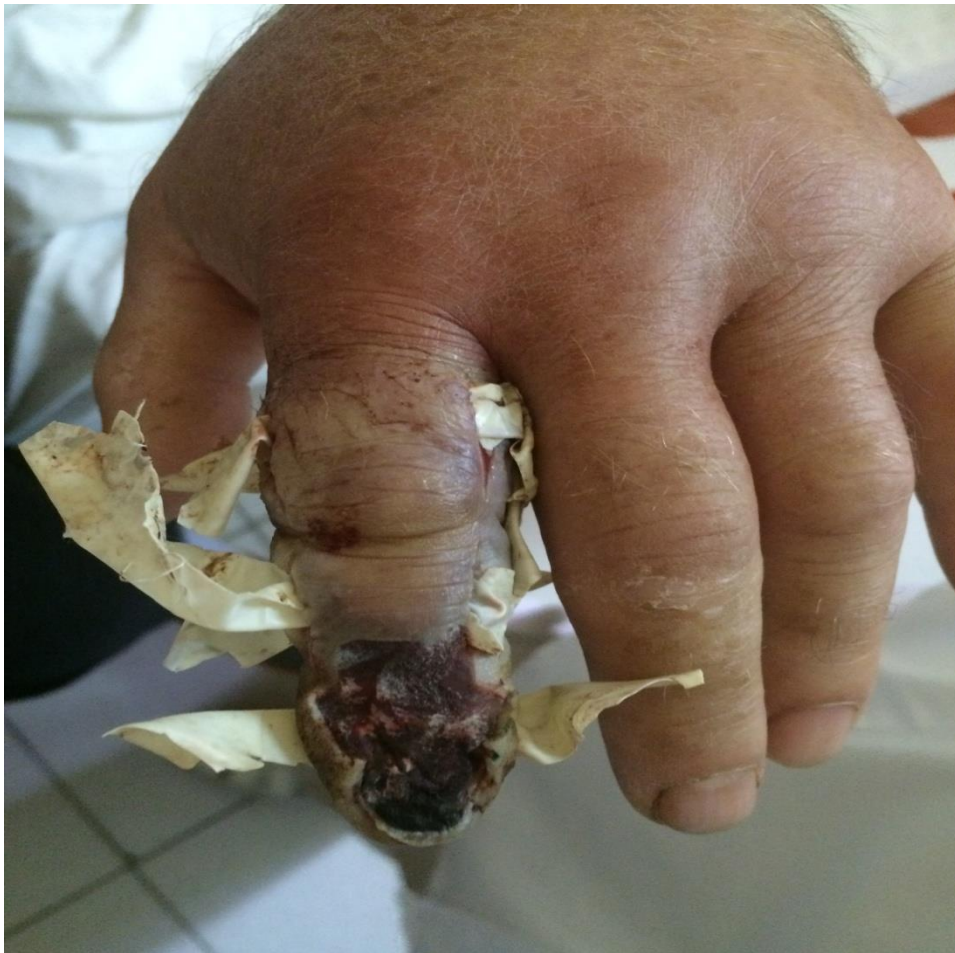Mastitis - inflammation of the parenchyma and interstitial breast. The vast majority of mastitis (80-85%) occur in the postpartum period in lactating women - lactational mastitis. More often in nulliparous, especially in women older than 30 years. There are also mastitis pregnant and non-pregnant women, chronic mastitis. Factors contributing to the development of mastitis: cracked nipples (entrance gate),

the presence of infection, the stagnation of milk, the weakening of the immunological reactivity of the mother's body in the first weeks after birth.

Treatment can be conservative and surgical. Conservative treatment - the exalted position of the breast, pumping milk UVR (ultraviolet blood irradiation), antibiotic therapy, retromammary novocaine blockade. Surgical treatment includes an autopsy, the release of pus drainage. To prevent mastitis is necessary to prepare the nipple for feeding during pregnancy, breast health, rational mode of feeding, reduction of birth trauma (pain, blood loss, and others.), Increase the body's resistance in the postpartum period (nutrition, walking).

Whitlow - acute purulent process, localized in the soft tissues of the fingers in the nail, as well as in bones and joints of the fingers. The infection penetrates microtrauma (abrasions, scratches, puncture wounds, and others.).

Whitlow divided into skin, subcutaneous, subungual, tendon, bone, joint and pandaktilit. The first four types panaritiums considered superficial, and others – deep (Fig.7).

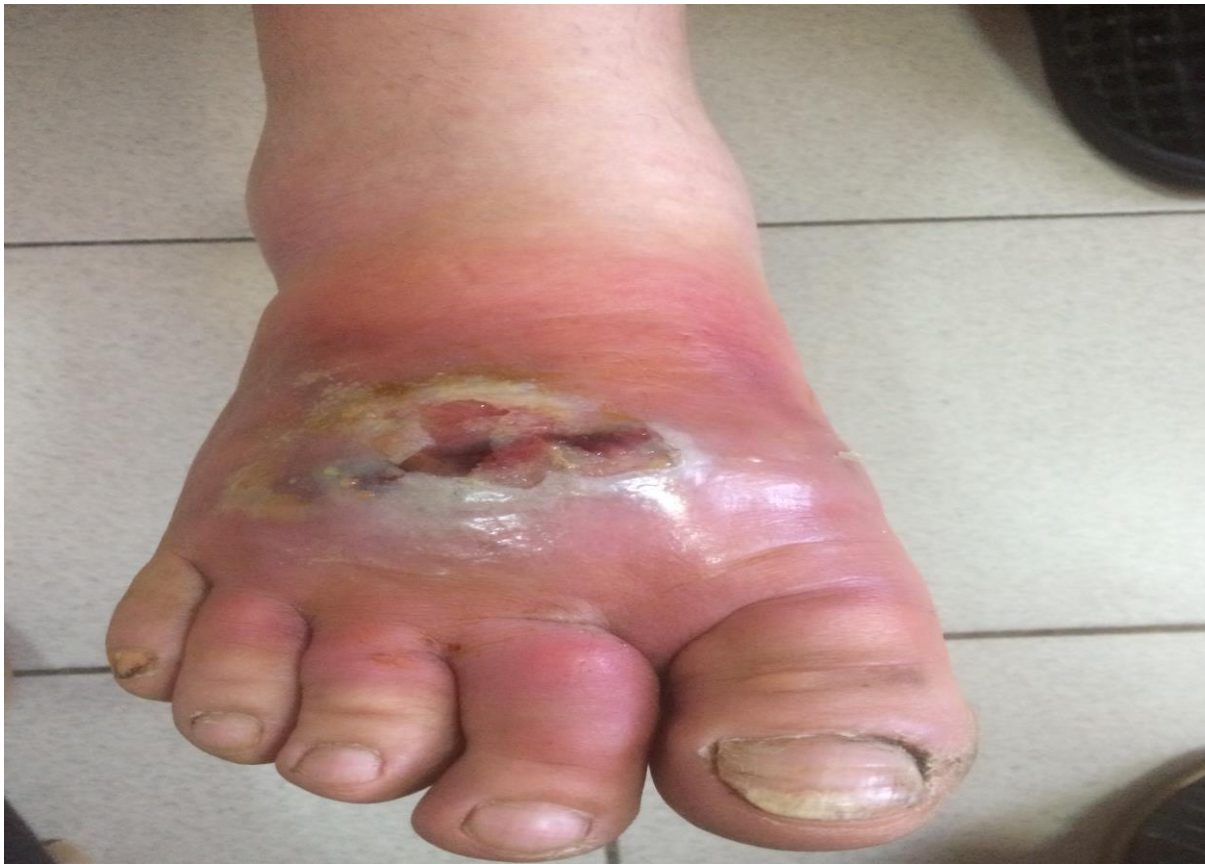

**Fig.7. Bone whitlow**

### **Cellulitis - phlegmon.**

Cellulitis (phlegmon )- an acute purulent inflammation of the spilled fat, do not tend to restrict, and has a tendency to spread along the fascial-cellular spaces (Fig.8).

In the overwhelming majority of cases, the immediate cause of the purulent process is pathogenic microorganisms, which penetrate the tissue spaces directly through a wound or abrasion or through lymphatic or blood vessels. Most often, cellulitis develops under the influence of *Staphylococcus aureus*, streptococcus is the second most common.



**Fig.8. Forming phlegmon**

Depending on the location distinguish subcutaneous, intermuscular, retroperitoneal abscesses and other types. By the nature of fluid distinguish purulent, hemorrhagic and purulent putrid form abscesses. Localization distinguish superficial and deep cellulitis. For an acute process, a quick onset is typical with temperature rise up to 39-40 ° C and higher, symptoms of general intoxication, thirst, severe weakness, chills and headache. With surface phlegmon, swelling and redness appear in the affected area. The affected limb increases in volume, is determined by an increase in regional lymph nodes.

In the process of phlegmon palpation, a sharply painful, immobile, hot to the touch formation without clear boundaries is revealed. The skin above it shines. The movements are painful, the pain also increases with a change in body position, so patients try to move as little as possible. Subsequently, in the area of inflammation, a softening zone appears - a cavity filled with pus. Pus can either burst out with the



formation of a fistula, or spread to neighboring tissues, causing their inflammation and destruction.

For deep phlegmon is characterized by the earlier appearance and more pronounced severity of common symptoms - hyperthermia, weakness, thirst, chills. There is a rapid deterioration of the condition, possible shortness of breath, lowering blood pressure, frequent weak pulse, headache, decreased urination, cyanosis of the limbs, and yellow skin.

Regardless of the location (deep or superficial), acute phlegmon progresses rapidly, capturing all new areas of fatty tissue, as well as adjacent anatomical structures, and is accompanied by severe intoxication. There are five forms of acute phlegmon.

Serous phlegmon. Develops in the initial stage. Serous inflammation predominates: exudate accumulates in the area of the affected area, cells of fatty tissue are infiltrated with leukocytes. Fiber acquires a gelatinous appearance and is impregnated with a watery turbid liquid. The border between diseased and healthy tissues is practically not pronounced. Subsequently, the serous form may become purulent or putrid.

Purulent phlegmon. There is a histolysis (melting of tissues with the formation of pus), resulting in a turbid, whitish, yellow or green exudate. Due to the melting of tissues in this form of phlegmon, the formation of ulcers, fistulas and cavities is often observed. With an unfavorable course of purulent phlegmon, inflammation spreads to neighboring tissues (muscles, bones, tendons), which are involved in a purulent process and are also subject to destruction. Pus spreads through "natural shells" - subfascial spaces and tendon sheaths. Muscles get dirty-gray color, soaked with pus and do not bleed.

Putrid phlegmon. It is characterized by the destruction of tissues with the formation of gases with an unpleasant odor. Fabrics with such cellulite acquire a dirty brown or dark green color, become slippery, loose and collapse, turning into a semi-liquid spreading mass. Putrid disintegration of tissues causes severe intoxication.

Necrotic phlegmon. Characterized by the formation of foci of necrosis, which subsequently either melt or reject, leaving behind a wound surface. With a favorable course of cellulitis, the area of inflammation is limited from the surrounding healthy tissues by leukocyte shaft, and later - by the granulation barrier. The inflammation is localized, in place of phlegmon abscesses are formed, which are either opened independently or drained by surgery.

Anaerobic phlegmon. There is a widespread serous inflammatory process with the emergence of large areas of necrosis and the release of gas bubbles from the tissues. The fabrics are dark gray, with a fetid odor. Palpation is determined by crepitus (soft crunch), due to the presence of gas. Tissues around the focus of inflammation get a “boiled” look, there is no redness.

Mandatory surgery.

Bandages with hypertonic solution or water-soluble ointments containing antibiotics are applied to the wound. Ointments on vaseline protein and fatty base (syntomycin emulsion, Vishnevsky ointment, neomycin, tetracycline ointment, etc.) are not shown in the early stages, since they impede the outflow of wound contents. In order to speed up the rejection of the dead spots, special necrolytic agents are used - proteolytic enzymes (proteases, chymotrypsin, trypsin) or enzymes containing ointments.

After cleansing the wound cavity, ointment dressings are used. Troxevazine and methyluracil ointment is used to stimulate regeneration, fat-based ointment is used to protect granulation tissue from damage, and water-soluble ointments are used to prevent re-infection.

Palm phlegmon. Germs get into the palm tissue through the microtrauma, or due to the spread of purulent process with the fingers in a proximal direction. In accordance with the localization of purulent process are the following purulent diseases of the brush:

Skin:

- a) skin abscess ("Namin");
- b) helotic abscess.

Subcutaneous tissue:

- a) nadaponevroticheskaya abscess palm;
- b) interdigital (commissural) abscess.

Fascial-cellular spaces palm:

- a) nadaponevroticheskaya abscess palm;
- b) the median palmar space abscess;
- c) abscess thenar (thumb elevation);
- d) abscess hypothenar (hypothenar).

Fascial-cellular spaces back of the hand:

- a) subcutaneous abscess;
- b) subgaleal abscess.

### **Treatment of purulent diseases.**

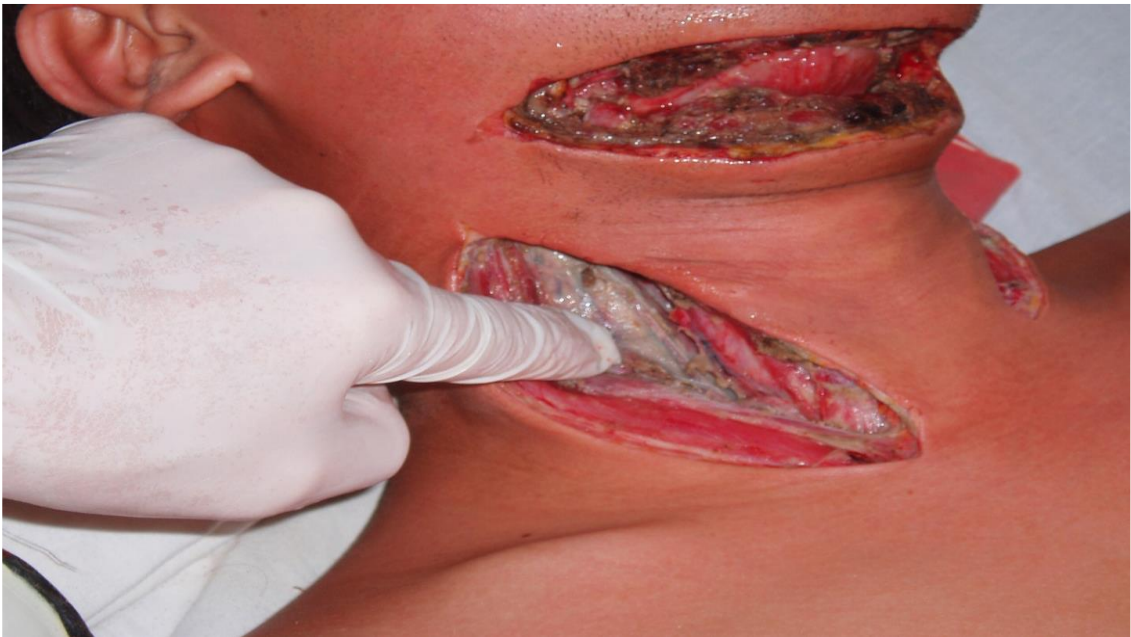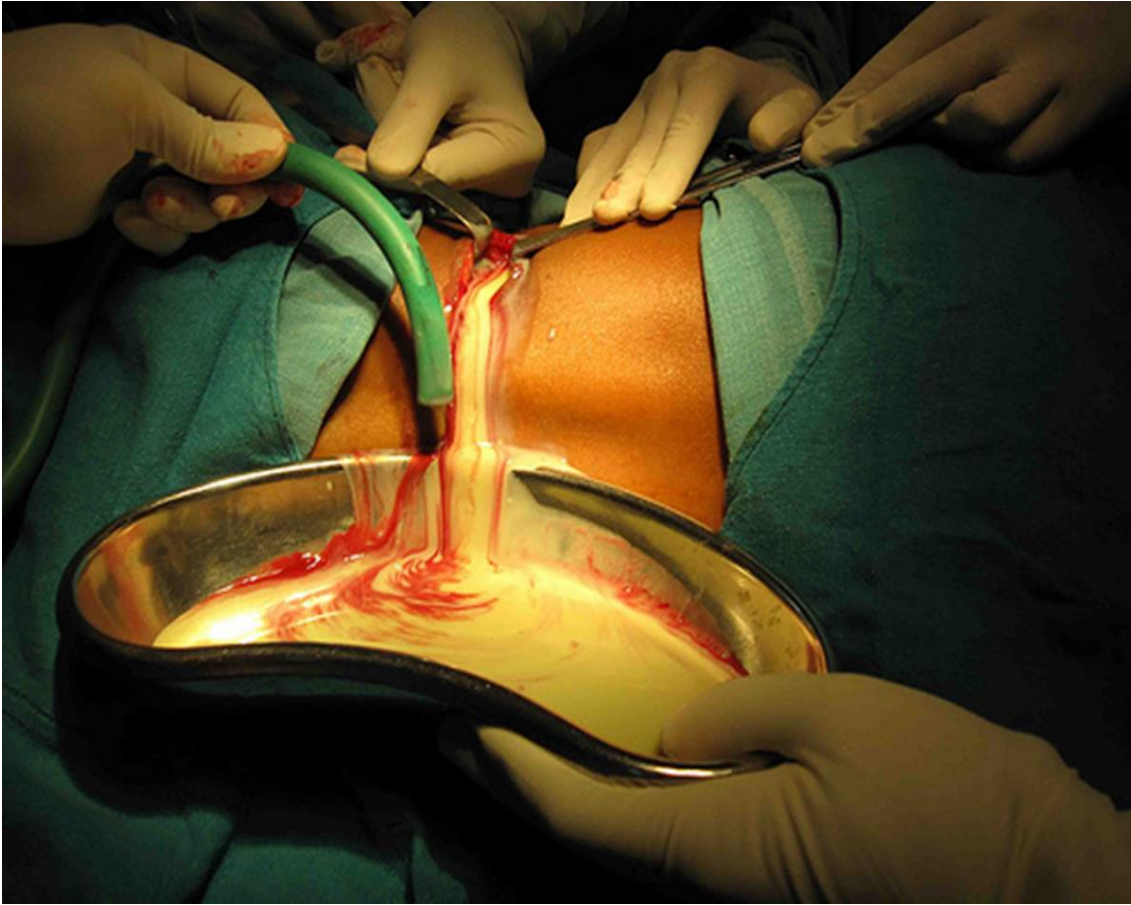
In the first stage serous-infiltrative, when there emerged purulent cavity shown conservative treatment is the application of cold, which promotes vasoconstriction, decreased exudation, edema, reduce the biochemical processes that inhibit the development of inflammation and subsequently its liquidation without development festering. The cold is applied in the form of a jet of cold water, if a finger or an ice pack, if the process is where you can not apply a jet of cold water.

The duration of exposure to cold should be about 20 minutes. then at the site of inflammation applied drying alcohol compress, which is a piece of bandage around a finger or a piece of gauze in 3-4 layers in other areas of the body used without compress paper. Gauze moistened poluspirtovyim solution (vodka, etc.). As the drying gauze wetted repeatedly with the same solution for 2 hours. Then again applied cold, and then drying again poluspirtovy compress. Said treatment is carried out for 2 days. If such treatment is started at the time the patients noted an improvement (decrease in pain, swelling, improved functions, etc.) and the end of the second day of locally introducing infection crust is formed which disappears and treatment terminates.

In the absence of the effect of the autopsy must be performed and drainage of purulent cavities (Fig.9).

To improve rejection of necrotic tissue after opening the abscess apply ointment water-based (levomikol, Levosin, levoporsin, dioksikol).

After cleaning the wound of necrotic tissue and the appearance of granulation apply ointment fat-based (solkoserilovaya ointment or Dog rose sea buckthorn oil, etc.).



**Fig.9. Excision the abscess in the operating room and under general anesthesia**

## Control tests

1. Symptom which are different for infiltrate stage and abscess stage :

- 1) pain;
- 2) hyperemia;
- 3) absent of fluctuation;
- 4) hyperthermia;
- 5) leukocytosis.

2. There are all the above options of whitlow , except:

- 1) dermal;
- 2) subcutaneous;
- 3) bone;
- 4) palm;
- 5) tendon.

3. Anatomical areas phlegmon of the palm include:

- 1) metacarpus, wrist;
- 2) metacarpus, wrist, fingers;
- 3) metacarpus and fingers;
- 4) wrist and fingers

4. Inflammation of the finger tissues is:

- 1) osteomyelitis;
- 2) panaritium;
- 3) tendovaginitis;
- 4) mastitis.

5. What local symptoms are not characteristic of purulent diseases:

- 1) pallor of the skin
- 2) a painful;
- 3) swelling; redness;
- 4) local temperature;
- 5) dysfunction.



## Literature

1. A guide to practical exercises on general surgery. In English. General surgery. The manual / Ed. VC. Gostishcheva - Publisher GEOTAR-Media, 2015. - 220 p.

2. General surgery [Electronic resource]: a textbook / VK Gostishchev. - 5 th ed., Pererab. and additional. - M.: GEOTAR-Media, 2015. - <http://www.studmedlib.ru/book/ISBN9785970432143.html>

3. General surgery [Electronic resource]: a textbook / Petrov S.V. - 4 th ed., Pererab. and additional. - M.: GEOTAR-Media, 2012. - <http://www.studmedlib.ru/book/ISBN9785970422816.html>

4. Petrov S.V. General surgery: a textbook. - Publisher of GEOTAR-Media, 2016. - 832p.

## CONTENTS

General data of purulent diseases.....	3
Boil – furuncle.....	7
Carbuncle.....	9
Hydradenitis. Abscess. Mastitis. Whitlow.....	11
Cellulitis - phlegmon .....	13
Treatment of purulent diseases.....	17
Control tests.....	19
Contens.....	20
Literature.....	21