


# Boys: Circumcision & Testicular Issues

**Abhishek Seth, MD, FRCS(C), FAAP**  
Urology

1



## Outline

<b>Acute Scrotum</b>	<b>Circumcision &amp; Penile Problems</b>
<ul style="list-style-type: none"><li>• Testicular torsion</li><li>• Torsion of the appendix testis</li><li>• Epididymitis/orchitis</li><li>• Incarcerated hernia</li></ul>	<ul style="list-style-type: none"><li>• Balanoposthitis</li><li>• Paraphimosis</li><li>• Hair tourniquet</li></ul>

2



## Acute Scrotum

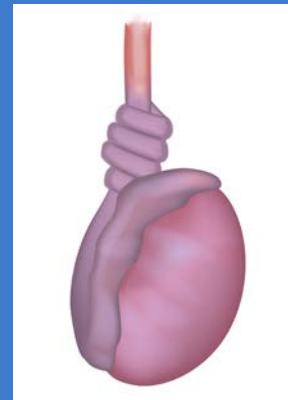
- Appendage torsion
- Testis torsion
- Epididymitis
  - Infectious
  - Sterile or traumatic
- Orchitis
  - Assoc. with epididymitis w/ or w/o abscess
  - Vasculitis (Henoch-Schönlein purpura)
  - Viral illness (mumps)
- Scrotal edema or erythema
  - Diaper dermatitis, insect bite, misc. skin lesions
  - Idiopathic scrotal edema
- Hernia or hydrocele
  - Inguinal hernia w/ or w/o incarceration
  - Communicating hydrocele
- Varicocele
- Intrascrotal mass
- MSK pain from inguinal tendonitis or muscle strain
- Referred pain (ureteral calculus or anomaly)

3



## Testis Torsion

- May occur at any age
  - Most common during adolescence
  - 31% prepubertal
  - 5% > 30 yo
- 1/4000 male patients under age 25
  - Average age 18.5
- Increased risk of contralateral torsion
  - Right sided : Left sided = 5:3



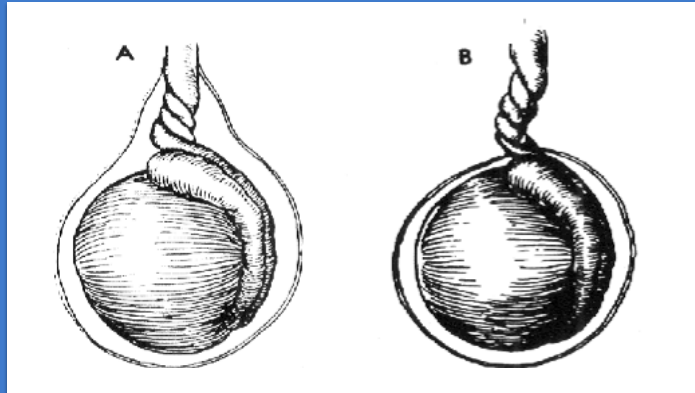
4



# What Causes Testicular Torsion?

Older Child

Neonate



Intravaginal Torsion

Extravaginal Torsion

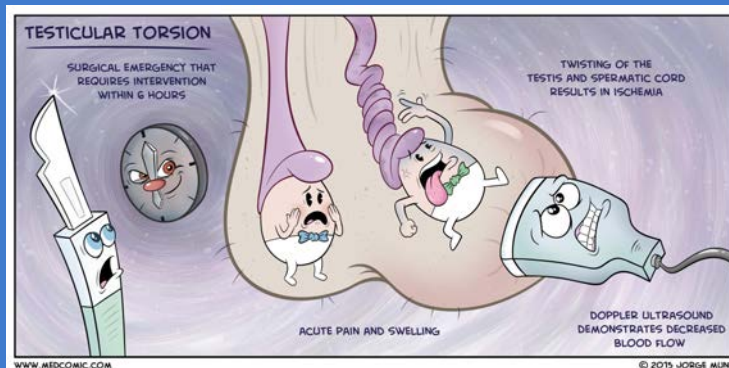
From "Torsion of the Testis" by L. L. Leape (p. 1331). In *Pediatric Surgery (4th ed.)*, by K. J. Welch, J. G. Randolph, M. M. Ravitch, J. A. O'Neill, Jr., & M. I. Rowe, 1986, Chicago: Year Book Medical Publishers

5



# Torsion in an Adolescent Male

- H&P
- Low suspicion
- High suspicion for torsion
  - Doppler ultrasound
- Go straight to OR
- ? Labs – Urine Analysis



6



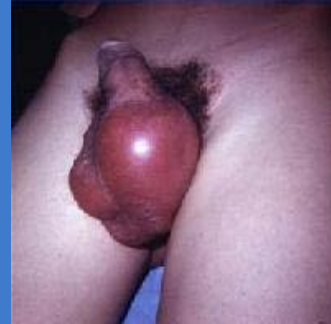## Signs and Symptoms

### Symptoms

- Sudden onset testicular pain
- Nausea/vomiting
- Mild pyrexia

### Signs

- Scrotal swelling
- Erythema
- Reactive hydrocele
- Abnormal testicular lie (high riding with a horizontal lie)
- Absent cremasteric reflex (only useful if present on non-affected side)

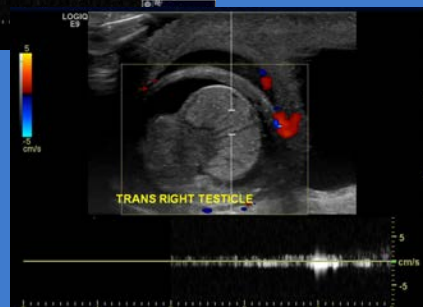
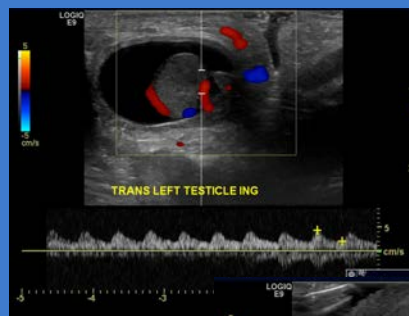


7



## Ultrasound in Diagnosis of Testicular Torsion

- Enlarged testis with abnormal echotexture
- Absent arterial waveform
- Reactive hydrocele
- Thickened hyperemic scrotal skin
- Sensitivity – 89%
- Specificity – 99% → ~1% false-positive rate



An Analysis of Clinical Outcomes Using Color Doppler Testicular Ultrasound for Testicular Torsion Baker, L. et. al (J. Hopkins) *Pediatrics*. 2000, 105(3), 604-7

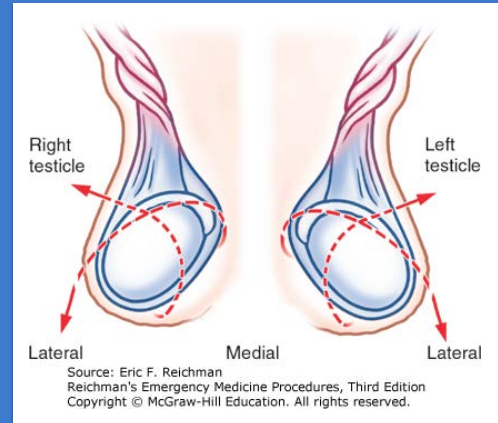
8



## Testicular Torsion: Treatment

### Manual Detorsion (controversial)

- “Open the book” or external rotation technique – but 25% torsed opposite direction!!!
- Not a substitute for surgical intervention – still need orchiopexy
- May provide earlier relief of symptoms and increase the rate of testis salvage



9



## Testicular Torsion: Treatment

- Emergent surgical exploration (mainstay)
  - Rate of testis salvage at 6 hours ~ 90%
  - @12 hours – 50%
  - @24 hours – 0%
  - **About 40% of cases result in loss of the testicle**
  - Must perform orchiopexy of affected testicle, if salvaged, and **contralateral testicle**
- Informed consent should always include discussion of possible orchiectomy, testis loss and/or testis atrophy long term

10



## Perinatal Testicular Torsion

- First described in 1897
- Almost exclusively due to **extravaginal** torsion
- Salvage rate is zero
- Controversy regarding
  - Necessity of surgery at all – no salvage
  - Need for contralateral orchidopexy
  - Timing of surgery/orchidopexy if performed
- Must weigh risk of neonatal anesthesia, injury to contralateral testis with risk of contralateral asynchronous torsion

11



## Perinatal Testicular Torsion

At Texas Children's, most urologists perform orchiectomy and contralateral orchidopexy at 3-6 months of age

Table 1 Standardized cases of unilateral prenatal, unilateral postnatal, and bilateral prenatal torsion and the surgical management decisions selected by survey respondents.

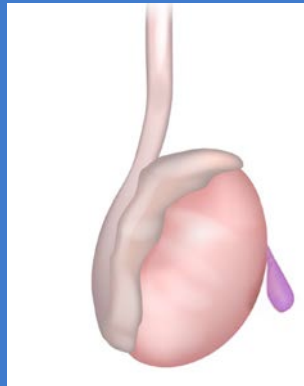
Case	Patient age	Immediate (%)	Urgent (%)	Elective (%)	None (%)
Prenatal torsion	3 h	43 (34)	31 (26)	33 (28)	15 (12)
Postnatal torsion	6 h	113 (93)	6 (5)	1 (1)	1 (1)
Bilateral prenatal torsion	3 h	109 (90)	1 (1)	2 (2)	9 (7)

12



# Torsion of the Appendix Testis

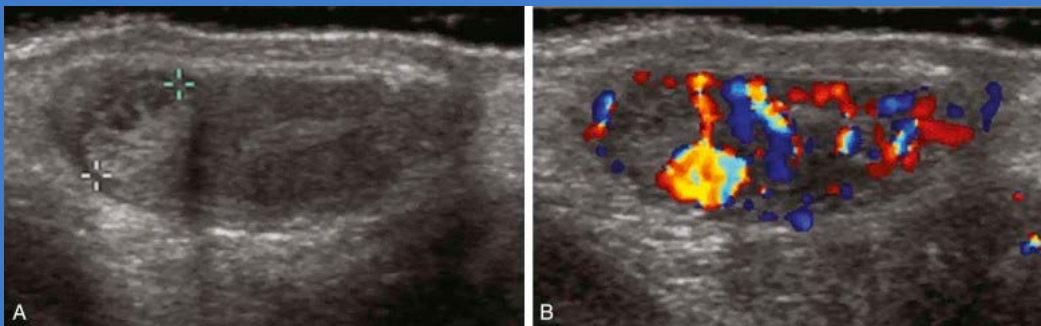
Way more common!



13



# Ultrasound

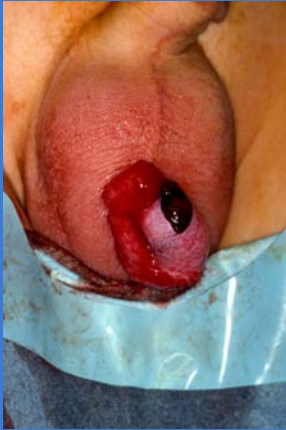

14



## Torsion of the Appendix Testis

“Blue Dot Sign”



### Treatment

- Observe
- Rest
- Ice
- Motrin

15



## Epididymitis in Prepubertal Boys

- Bacterial vs. non-bacterial
- Many cases of “epididymitis” are actually torsion of appendix testis – treatment of non-bacterial epididymitis and torsion of appendix testis is the same
- Association pyuria and/or bacteriuria is reported in **20% to 40% of cases**
- Pre-pubertal boys and boys w/o hx of instrumentation or sexual activity with **culture-proven** epididymitis → renal/bladder US and VCUG AFTER infection is treated

### Non-bacterial

- Ice packs
- NSAIDs
- Scrotal elevation
- Rest to avoid traumatic exacerbation

### Bacterial/Pyuria

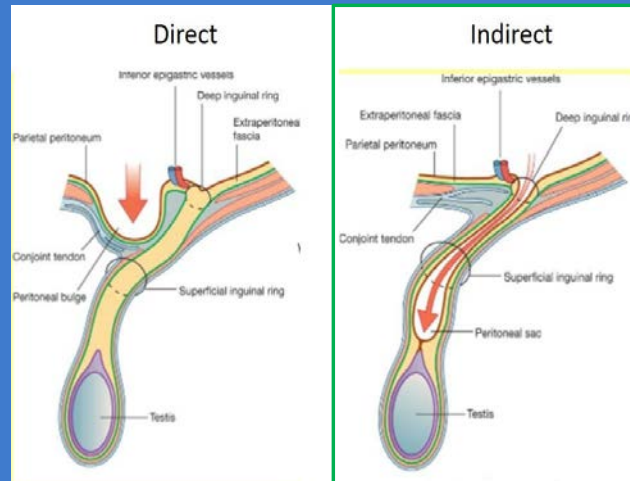
- Send cx
- Give broad-spectrum antibiotics with gram-negative coverage (Bactrim, avoid Cipro in kids)

16





## Incarcerated Hernia



17



## Circumcision

### 2012 AAP Policy Statement on Circumcision

After a comprehensive review of the scientific evidence, the American Academy of Pediatrics found **the health benefits of newborn male circumcision outweigh the risks, but the benefits are not great enough to recommend universal newborn circumcision.**

The AAP policy statement published Monday, August 27, 2012 says the final decision should still be left to parents to make in the context of their religious, ethical and cultural beliefs.

18



## Circumcision: Office or Operating Room?

- Most will do newborn circumcisions only up to 30 days and 10lb
  - Some providers go above these limits
- Refer newborns ASAP from hospital or first newborn well check
- After this cutoff – circumcision will need to be done in the OR
- Abnormalities of the penis/foreskin will be done in the OR
  - Hypospadias, chordee, severe penile torsion, severe penoscrotal webbing, asymmetrical or incomplete foreskin
- OR circumcisions done after 6 months of age

**Refer ASAP – elective circumcision not covered >1 year of age**

19



## Care of the Uncircumcised Penis

- Phimosis is normal in babies and toddlers – never forcibly retract the foreskin
- Slowly and gently stretch the skin over time
- Phimosis after age 4 or if having symptoms – treat with topical steroid cream
  - Betamethasone valerate 0.1% TID x 6 weeks



20



## Circumcision Indications

- Pathologic phimosis – balanitis xerotica obliterans
- High-grade vesicoureteral reflux in an infant
- Failure of topical steroid
- Recurrent balanoposthitis
- Recurrent paraphimosis



21



## Complications After Circumcision

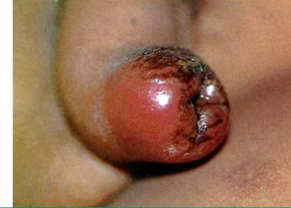- Penile adhesions
  - Skin bridge vs. soft adhesions
- Redundant foreskin
  - Usually not redundant when suprapubic fat pad is pushed down
- Cicatrix/concealed penis
- Meatal stenosis
  - Causes deflected or abnormal urine stream

22



## Balanoposthitis

- Inflammation of the glans penis and the foreskin in uncircumcised males
- 4% of uncircumcised boys, mostly between 2-5 years of age
- Causes: irritation, trauma, contact allergy, poor hygiene, infection (bacterial and candida)



This uncircumcised boy developed a moderately severe case of balanoposthitis.

Reproduced with permission from: *Genitourinary Emergencies. In: Atlas of Pediatric Emergency Medicine. Fleisher GR, Ludwig S, Baskin MN (Eds), Lippincott Williams & Wilkins, Philadelphia 2004. Copyright © 2004 Lippincott Williams & Wilkins. [www.lww.com](http://www.lww.com).*

UpToDate®

23



## Balanoposthitis – Treatment

- Proper hygiene, avoidance of forced retraction of the foreskin in the young boy, avoidance of irritants, Sitz baths, antibiotic ointment
- Bactroban or Bacitracin ointment → coverage against Staph and Strep; can prevent secondary infection of irritated foreskin
- Don't use triple antibiotic ointment → has neomycin, can cause dermatitis



24



## Balanoposthitis – Treatment

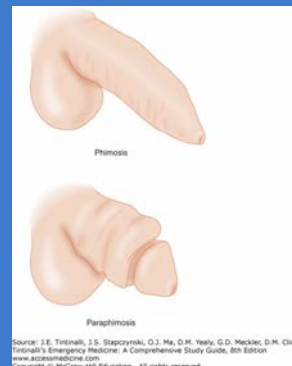
- If suspect **Group A Strep** → culture and treat like pharyngitis!!
- After inflammation resolved, can treat with 0.05-0.1% betamethasone cream to improve phimosis for 2-6 weeks
- Foreskin hygiene
- Circumcision in cases of repeated balanitis with associated phimosis not responsive to steroid cream

25



## Paraphimosis vs. Phimosis

- Physiologic phimosis is normal until ~3 years of age
- If phimosis does not resolve by ~3 years of age or child has recurrent balanitis → topical steroid cream, circumcision
- **NEVER** forcefully retract phimotic foreskin!!!



26



## Paraphimosis vs. Phimosis

- Longer duration of paraphimosis → more difficult to reduce
- Often requires squeezing of edema from tissues to aid with reduction of paraphimosis
- May need local anesthesia or sedation
- If cannot be reduced manually – surgical reduction with dorsal slit with/without circumcision

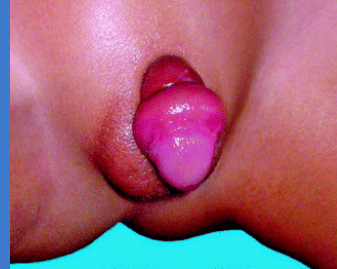
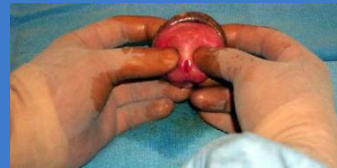
Image courtesy of Seattle Children's Hospital Department of Urology

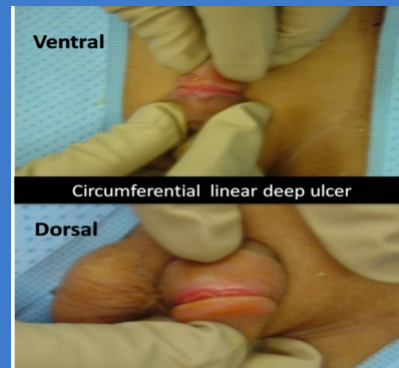


27



## Penile Hair Tourniquet

- Hair tourniquet – surgical emergency similar to paraphimosis in appearance
- Ischemic injury to the glans may occur if not relieved promptly by division and removal of the hair strand
- Hair strand often difficult to see and can best be done with aid of sedation of child and surgical loupes



Hair-thread tourniquet syndrome in a child penis: Case report and review of literature  
H Al-Hazmi, A Ali, T Al Harbi, B Almussallam

28