

## Odontogenic phlegmon of the mouth floor: a case report

Bortnik P.<sup>1A-F</sup>, Wieczorek P.<sup>2 A-F</sup>, Załęski P.<sup>1 A-F</sup>, Kosierkiewicz P.<sup>C</sup>, Siemiątkowski A.<sup>C</sup>, Tryniszewska E.<sup>F</sup>, Borys J.<sup>D-F\*</sup>

1. Department of Maxillofacial and Plastic Surgery, Faculty of Medicine, Medical University of Białystok, Białystok, Poland
2. Department of Microbiological Diagnostics and Infectious Immunology, Faculty of Pharmacy, Medical University of Białystok, Białystok, Poland
3. Department of Anaesthesiology and Intensive Care, Faculty of Medicine, Medical University of Białystok, Białystok, Poland

---

**A**- Conception and study design ; **B** - Collection of data; **C** - Data analysis; **D** - Writing the paper; **E**- Review article; **F** - Approval of the final version of the article; **G** - Other

---

### ABSTRACT

---

Odontogenic phlegmon of the mouth floor—Ludwig's angina (*phlegmonae fundi cavi oris seu angina Ludovici*)—is a rare, life-threatening, local complication in most cases of odontogenic inflammation. This study presents the case of a patient treated in the Department of Maxillofacial and Plastic Surgery of the University

Hospital in Białystok due to phlegmon of the mouth floor resulting from odontogenic inflammation with a dynamic course. Quick diagnostics, surgical intervention as well as antibiotic therapy contributed to its efficient and successful treatment.

**Key words:** Phlegmon of the mouth floor, odontogenic inflammation

---

DOI: 10.5604/01.3001.0009.5166

#### \*Corresponding author:

Jan Borys  
Department of Maxillofacial and Plastic Surgery  
Medical University of Białystok  
Sklodowskiej-Curie 24A Str., 15-276 Białystok, Poland  
Tel.: +48 85 7468379; Fax: +48 85 7468524, e-mail: kchszt@umb.edu.pl

Received: 16.07. 2016

Accepted: 08.12.2016

Progress in Health Sciences

Vol. 6(2) 2016 pp 178-183

© Medical University of Białystok, Poland

## INTRODUCTION

Odontogenic phlegmon of the mouth floor—Ludwig's angina (*phlegmonae fundi cavi oris seu angina Ludovici*)—is a rare, life-threatening, local complication in most cases of odontogenic inflammation. Pathogens and their toxins penetrating via the open tooth apex cause the inflammatory reaction within the periodontium, bone, and periosteum [1]. The structure and anatomical conditions of the facial part of the cranium and the neck influence the dissemination route of inflammatory processes. The infection from the primary focus located within the oral cavity, the face, and the neck disperses to the neighboring anatomical spaces via continuity and the route of blood and lymphatic vessels as well as along the neurolemma [2-4].

According to the literature data, 90% of all tissue inflammations within the face and oral cavity are odontogenic. It is thought that two-thirds of them were caused by dental pulp gangrene. An odontogenic focus of the inflammation, and developing on its base inflammatory infiltration, abscess, and phlegmon in the surrounding soft tissue may be the source of inflammatory processes located in the regional and distant soft tissues, such as in the mediastinum, facial bones of the skull, paranasal sinuses, orbit, cavernous sinus, meninges, and the cerebrum as well as the spinal canal [5]. Complications of odontogenic inflammatory processes most frequently result from patients' ignorance of the disease and reporting late to the doctor's office, impaired immune system, virulent bacterial flora, and, sometimes, an improper clinical diagnosis and administration of ineffective treatment [6]. A generalized inflammatory process in the form of sepsis or pyosepticaemia or metastatic abscesses may lead to permanent disability or even death. A proper diagnosis, recognition of the infection source, and early institution of the therapy decide the outcome of the treatment.

## CASE PRESENTATION

A 36-year-old patient was admitted to the Department of Maxillofacial and Plastic Surgery of the University Hospital in Bialystok as an emergency case due to 24-hour development of painful oedema of the neck, dyspnoea, and difficulties in biting, chewing, and swallowing food. For a week, the patient complained of pain in the lower molars and in the left side of the face. A fear of dental treatment deterred him from a dental visit. For 24 hours prior to hospital admittance the patient took an antibiotic of which name he did not remember, prescribed by a family doctor. The

antibiotic therapy caused no improvement in the general and local health conditions. The patient reported no complaints and disorders of other systems and organs.

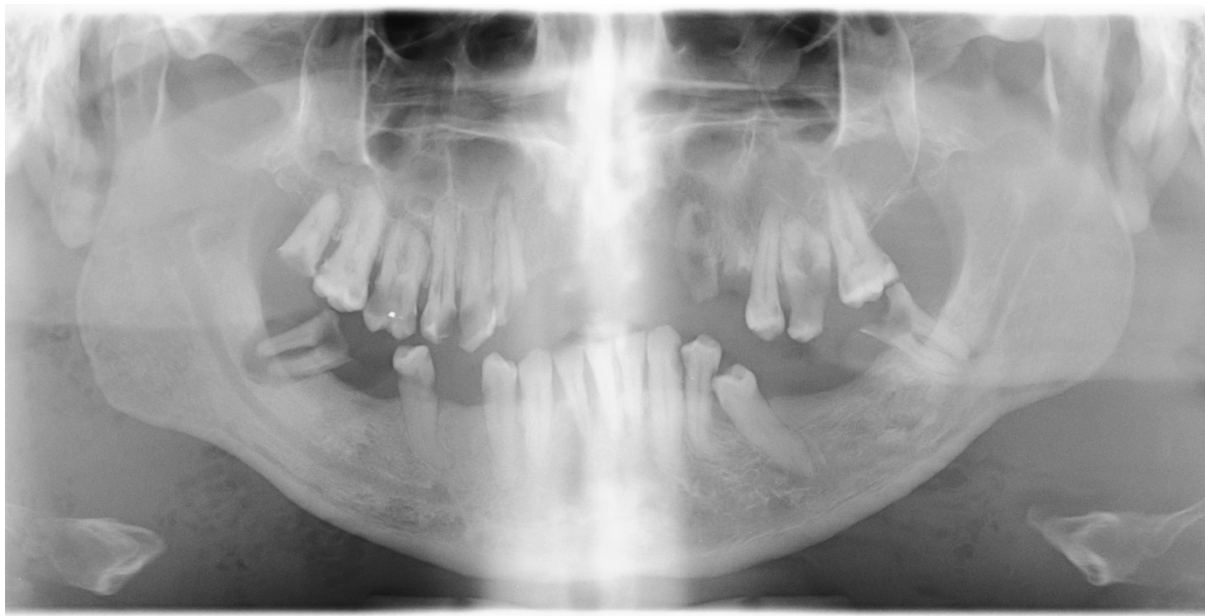On subjective examination, the patient was attentive, in serious general state, pale, sweaty, in logical verbal contact, taking a seated position due to respiratory dyspnoea. The patient presented a normal body build of a normosthenic type. The thorax symmetrically arched with normal breathing movements. The normal respiratory alveolar murmur was heard over the pulmonary fields. The frequency of breaths was 14/min. and saturation of 98%. The heartbeat was regular at 105/min., with medium loud and clear heart sounds of normal accentuation. Blood pressure was RR=120/70 mm Hg. The abdomen was soft and painless without peritoneal symptoms, with normal peristalsis. The patient's assessment according to the Glasgow Coma Scale was 15 points; in the RTS scale, 12 points. The body temperature was 36.8°C.

Extraoral examination revealed widespread inflammatory swelling of the face and the neck of limited motion, with visible sweating on the forehead and temples. The skin of both cheeks, the anterior neck surface, and the upper part of the thorax were abnormally warm, reddened, pale on pressure, taut, and painful. On palpation the lymph nodes of the neck were inaccessible due to an inflammatory reaction of the soft tissues.

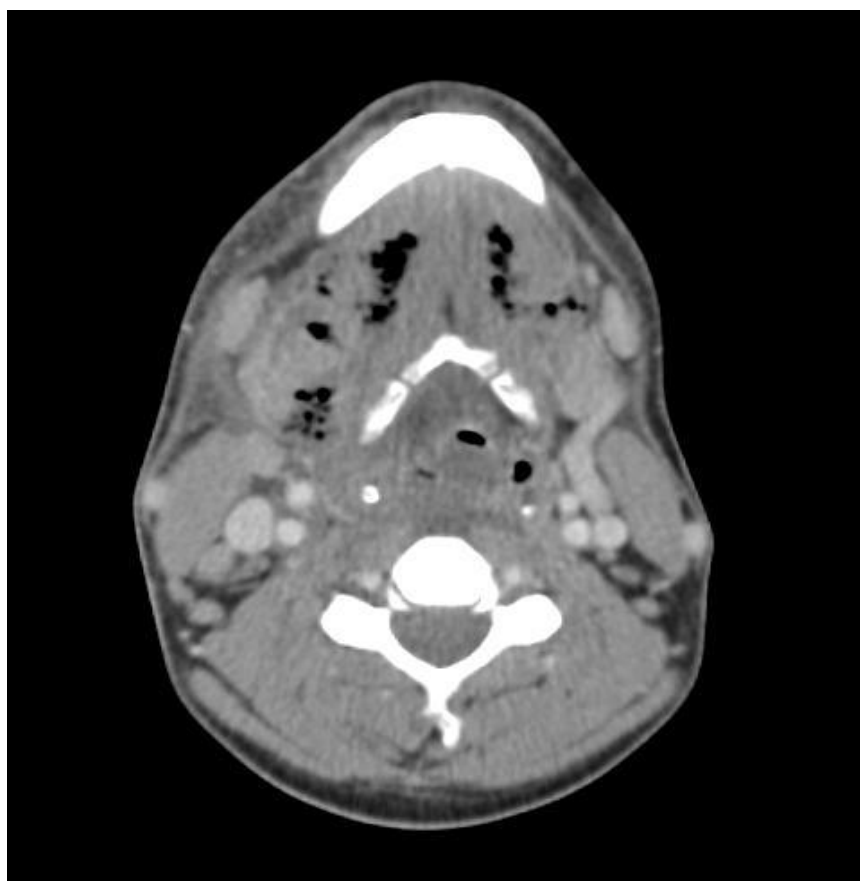
Intraoral examination showed limited jaw opening—II degree trismus and halitosis (*fetor ex ore*). The bottom of the oral cavity was elevated and swollen, with purulent discharge and reddened mucosa in the sublingual region. The tongue was swollen with a grey coating on its dorsal surface and markedly limited motion. Numerous remaining roots of teeth 18, 13, 23, 24, 48 and teeth 16, 15, 14, 26, 38, 45 with extensive cavity caries and the putrescent pulp were observed. Carious lesions mentioned above were confirmed by pantomography (Fig. 1). Palatal tonsils were normal.

The patient underwent laboratory tests, radiography and ECG. The results of the laboratory tests showed WBC 24.43 G/l; RBC 3.74 T/l; HGB 12.2 g/dl; HCT 35.3%; PLT 212 G/l; Na 131.0 mmol/l; K 4.62 mmol/l; CRP 489.7 mg/l; fibrinogen 960 mg/dl; procalcitonin 8.91 ng/ml; prothrombin time 13.3 sec.; Quick's index 100%; INR 1.00; kaolin cephalin time 36.3 sec. ECG recordings were normal.

CT of the craniofacial part of the body, the neck, and the thorax revealed extensive fluid reservoirs with numerous gaseous bubbles widespread from the level of the subtemporal fossa to the level of the discoid cartilage with the swollen subdermal tissue of the neck without pathological reservoirs within the mediastinum (Fig. 2).



**Figure 1.** X-ray of the skull—panoramic radiograph. Numerous tooth roots are visible mainly in the mandible accompanied by periapical lesions



**Figure 2.** CT scan of the neck. Fluid reservoirs with numerous gaseous bubbles, oedema of the subdermal tissue, minor lymphatic nodes, and the narrowing of the throat isthmus are seen in the picture at the level of the hyoid

Diagnosis of odontogenic phlegmon of the mouth floor was made based on the subjective, objective examination and accessory investigations.

After admission to the Department of Maxillofacial and Plastic Surgery, intensive wide-ranging antibacterial treatment was instituted—2 g

cefazolin, 1 g metronidazole and 0.5 g amikacin administered intravenously, rehydration with 500 ml multi-electrolyte solution, 500 ml 0.9% NaCl plus 20 ml 10% NaCl, and analgesic treatment with 0.1 g ketoprofen and 0.5 g vitamin C. After compensation for hydroelectrolytic imbalance, and general endotracheal anesthesia with nasal intubation, repeated incision of the neck with purulent drainage was performed. The teeth and tooth roots with putrescent pulp were extracted. During the procedure, purulent exudates were taken from the phlegmon lodges in the neck for microbiological examination. After the procedure, the patient—in a very serious general condition—was moved to the intensive care unit (ICU) due to cardiorespiratory failure with respiratory arrest. The culture of purulent bloody discharge from the phlegmon incision showed an anaerobic bacterium—*Fusobacterium nucleatum*, resistant only to vancomycin (Table 1).

**Table 1.** The result of microbiological examination - pus exudates obtained in phlegmon incision constitute the material

<i>Fusobacterium nucleatum</i>	
Amoxicillin	S
Amoxicillin/Clavulanic Acid	S
Benzylpenicillin	S
Clindamycin	S
Imipenem	S
Metronidazol	S
Moxifloxacin	S
Piperacillin	S
Piperacillin/Tazobactam	S
Rifampicin	S
Ticarcillin	S
Ticarcillin/Clavulanic Acid	S
Vancomycin	R

S—susceptible, R—resistant

During his stay in the ICU, the patient was ventilated mechanically, initially via endotracheal and later tracheostomy tube, supported with circulation-restoring catecholamines, intravenous antibiotic therapy of wide spectrum (1 g cloxacillin four times per day, 0.4 g gentamicin in 500ml of 0.9% NaCl in a continuous infusion, 0.5 g metronidazole three times per day, 0.5 g imipenem three times per day), intravenous rehydration (colloids, crystalloids), parenteral feeding (feeding bag), and enteral therapy (Protison). The patient had a temperature up to 39°C from day 3 to day 18 of his stay in the ICU. After two weeks in the ICU, a sample of bronchial discharge was taken and cultured. *Pseudomonas aeruginosa*, the strain producing metallo-beta-lactamase (MBL), susceptible only to colistin, was cultured.

Consequently, 2,000,000 colistin units three times per day introduced into the therapy on day 17 of the patient's ICU stay. Gradual improvement in the patient's general and local health states was observed. After three weeks of treatment, no purulent flow from drains was observed, and on day 21 of his ICU stay, the patient was taken off the respirator. On day 26 of his ICU stay, the patient, with restored circulatory-respiratory functions and breathing via a tracheostomy tube, was moved to the Department of Maxillofacial and Plastic Surgery for further specialist treatment. During the patient's stay in the department, intravenous antibiotic therapy was continued and enteral feeding of a drain diet was applied, initially by means of a stomach probe and later orally. On day 4 a tracheostomy tube was removed. The patient was rehabilitated by a physiotherapist to improve functioning of the extremities after the long immobilisation period. After a forty-six days of total treatment, the patient was discharged home with a recommendation for checkup in the Outpatient Dental and Rehabilitation Departments.

## DISCUSSION

Odontogenic phlegmon of the mouth floor is an acute, purulent, disseminated inflammation of the loose connective tissue, spreading quickly, without marked borders, affecting submandibular, submental, and sublingual spaces, which can develop into the most severe, frequently life-threatening form of purulent inflammation [7]. In the case reported in this paper, submental, sublingual, and both submandibular spaces were found to be affected with infiltration to both buccal spaces and walls of the lower parts of the neck and the upper parts of the anterior surface of the thorax.

Respiratory dyspnoea, pain, and oedema in the site of the mouth floor as well as speech and swallowing difficulties are often reported in the medical history of patients with phlegmon of the mouth floor. On objective examination, trismus, redness and inflammatory oedema of the mucosa of the mouth floor and the skin of the face and neck, and pain on palpation are frequently observed. A patient's general state is serious with chills, fever, and tachycardia [7]. The patient discussed in this case report also complained of the ailments mentioned above apart from chills and fever. Due to dyspnoea he took a seated position facilitating respiration. Severe pain and swelling of the mouth floor prevented the patient from eating and drinking, which led to hydroelectrolyte imbalance confirmed by blood biochemistry. Pharmacotherapy had to be instituted before any surgical procedure.

Many authors underline a significant influence of decreased immunity of the human body and comorbidity of systemic or metabolic diseases on development of the odontogenic complications [7]. In his medical history, the patient reported no

systemic disorders. On admission to the Department of Maxillofacial and Plastic Surgery, the patient's body temperature was normal (36.8°C), despite significant leukocytosis (WBC 24.43 G/l) and increased parameters of inflammation: CRP 489.7 mg/l, fibrinogen 960 mg/dl, procalcitonin 8.91 ng/ml. In the case of phlegmon, this condition may suggest a decreased defense response of the organism.

Several accessory investigations are recommended, including CT of the facial cranium structures, prospectively of the thorax, when the mediastinum involvement is suspected. In typical tomography, encysted fluid reservoirs with gaseous bubbles are found in the soft tissue of the mouth floor and the neck, with oedema of the subdermal tissue of the neck and obturation of the airways [8]. In the patient's tomography of the head, neck, and chest, extensive fluid reservoirs with numerous gaseous bubbles were observed widespread on the right from the level of the subtemporal fossa, the mandibular angle, along the paracentral mandibular surface bilaterally, and within the mouth floor. The oral part of the throat was swollen, the epiglottis hardly visible, the lower throat was constricted, the vestibule of the larynx narrowed, and numerous small lymph nodes were found in the neck. No enlarged lymph nodes within the mediastinum and pathological reservoirs were observed within the mediastinum. X-ray images enabled the determination of the extensity of inflammation within the interfascial spaces of the neck and simultaneously excluded the spreading of the inflammatory process to the mediastinum at the moment of examination. Stenosis of the isthmus and the laryngeal opening due to the inflammatory process found in CT imaging showed the cause of respiratory dyspnoea observed in the patient. The presence of gaseous bubbles accompanying the fluid reservoirs suggested developing phlegmon of the neck requiring urgent surgical intervention.

Treatment of phlegmon of the mouth floor involves surgical treatment: incision and drainage of pus reservoir, extraction of the teeth, and pharmacotherapy—mainly antibiotic therapy as well as the patient's rehydration, decreasing the body temperature, and administration of analgesics [7]. Similar management was applied in our patient's therapy. Surgery was performed after compensation of hydroelectrolyte imbalance, pain relief, and therapeutic antibiotic treatment, which concentration was determined by blood tests. General endotracheal anesthesia with nasal intubation, incisions, and contraincisions of the neck skin were performed, reaching the pus reservoirs, which were drained, enabling purulent exudates to flow freely. During the same procedure, the teeth and tooth roots with gangrenous decay were excreted to eliminate the infectious foci—the cause of phlegmon of the mouth floor. Such pharmacological and therapeutic

management performed within a few hours after the patient's admission to the department is optimal treatment, enabling the fastest recovery from inflammation.

Nonodontogenic and odontogenic inflammatory conditions of the facial part of the skull and the neck, most frequently resulting from gangrene of the tooth pulp and its complications, are the cause of the development of phlegmon. In our patient, phlegmon of the mouth floor was caused by the remaining roots of tooth 48 and teeth 38 and 45 with extensive carious cavities and putrescent pulp. Additionally, gangrene of the pulp was revealed in roots of teeth 18, 13, 23, and 24 and teeth 16, 15, 14, and 26. According to the general guidelines [1], the teeth and tooth roots causing purulent inflammation and the teeth with gangrenous decay were extracted during the procedure of incision and drainage of phlegmon.

The type of bacterial flora causing inflammation is of vital importance. The material obtained during surgical evacuation of exudates should be sent for bacteriological examination to determine pathogenic microbes and their sensitivity to antibiotics. Phlegmon of the neck is most frequently caused by infection with mixed aerobic and anaerobic flora with various pathogens. Gram-positive, Gram-negative bacteria, especially streptococcus (*Streptococcus* spp.) and staphylococcus (*Staphylococcus* spp.), are the most frequent causes of interfascial infections [9]. In the reported case, odontogenic infection was caused by anaerobic Gram-negative bacilli *F. nucleatum* resistant to vancomycin. Later, *P. aeruginosa*, sensitive only to colistin, was cultured from the bronchial tree, which was related to mechanical ventilation of the lungs in the ICU. In the initial stage of treatment, empirical antibiotic therapy of wide spectrum comprised the range of antibacterial activity against the isolated microbes. However, later targeted antibiotic therapy was used, enabling regression of inflammation.

In the treatment of phlegmon of the mouth floor it is vital to secure the patency of the upper airways, especially in patients with intensified dyspnoea and trismus. It is believed that maintenance of airway patency is a priority procedure in treatment of infections of the deep spaces of the neck with impaired respiration [10]. The patient presented in this case report required further treatment in the ICU, with mechanical ventilation, initially via an endotracheal tube, supported by intravenous infusions of catecholamines due to circulatory-respiratory failure, following incision and drainage of phlegmon. In consequence of a prolonged period of mechanical ventilation and trismus, tracheotomy was performed on day 14 of the ICU stay. This procedure facilitated proper ventilation of the patient with intensive inflammatory oedema of the mouth

floor, impairing the patency of the upper respiratory tract and opening of the jaws.

In the case report presented, phlegmon of the mouth floor was the consequence of the patient's hygienic negligence of the oral cavity. The acute life-threatening odontogenic inflammatory process that developed in the patient was caused by the foci of infection—teeth and tooth roots with gangrene of the roots left in the oral cavity. Dental caries leading to pulp gangrene and its complications (including pathological gingival pockets) and inflammation developing on the follicular cysts can be the cause of regional abscesses and phlegmons, bacteraemia, endocarditis, brain abscesses, mediastinitis, and other general complications threatening a patient's life [11]. Thus, regular dental checkups are very important for maintenance of proper health conditions of the oral cavity. It should be emphasized that dental examination and imaging diagnostics of the stomatognathic system have to be performed to search for the odontogenic foci of infection [12]. To eliminate the risk of severe complications related to odontogenic infectious foci, it is absolutely necessary to maintain sanitation of the oral cavity [8]. Irrational fear of a dentist and abandonment of dental treatment may lead not only to life-threatening conditions but to death as well.

## CONCLUSIONS

Odontogenic phlegmon of the mouth floor is an inflammatory process of a severe, rapid course with serious life-threatening complications. Institution of intensive multispecialist treatment makes it possible to save a seriously ill patient's life and restore health.

## Acknowledgements

We thank Steven Snodgrass for editorial assistance.

## Conflicts of interest

The authors declare that there is no conflict of interest that could be perceived as prejudicing the impartiality of the review reported. There is no financial or other potential conflict of interest.

## Funding

This research did not receive any specific grant from any funding agency in the public, commercial, or not-for-profit sectors.

## REFERENCES

1. Semadani-Konopacka I. Postępowanie z zębem przyczynowym w ostrych sprawach okołoszczękowych i zapaleniach kości. *Czas Stomat.* 1978;XII:755-61. (Polish)
2. Haug R, Hoffman MJ, Indresano T. An epidemiologic and anatomic survey of odontogenic infections. *J Oral Maxillofac Surg.* 1991 Sep;49(9):976-80.
3. Larkin EB, Scott SD. Przerzutowy ropień okołokręgowy i porażenie kończyn dolnych w następstwie ekstrakcji zębów. Przypomnienie poważnych następstw infekcji w jamie ustnej. *Magazyn Stomat.* 1995;2:33-5. (Polish)
4. Schuman NJ, Turner JE. Ropień mózgu a stomatologia. *Przegląd piśmiennictwa. Quintessence.* 1994;II,10:685-7. (Polish)
5. Izadi K, Lazow SK, Berger JR. Mediastinitis secondary to an odontogenic infection. A case report. *N Y State Dent J.* 2003 Dec;69(10):28-30.
6. Sancho LMM, Minmoto H, Fernandez A, Sennes LU, Jatene FB. Descending necrotizing mediastinitis: a retrospective surgical experience. *Eur J Cardiothorac Surg.* 1999;Aug 16(2):200-5.
7. Kryst L. Chirurgia szczękowo-twarzowa. Warszawa: PZWL;2009,133-4. (Polish)
8. Wanyura H, Chabowski M, Kuca R, Kamiński A, Orłowski TM, Kowalska K. Zstępujące martwicze zapalenie śródpiersia – powikłanie procesu zapalnego w obrębie tkanek twarzy i szyi. *Czas Stomat.* 2005;LVIII,9:658-66. (Polish)
9. Kawczyński M, Amernik K, Kelar I, Jaworowska E, Paradowska-Opalka B. Zakażenia ropne głębokich przestrzeni szyi w Klinice Otolaryngologii PUM w okresie ostatnich 5 lat. *Pol. Przegląd Otorinolaryngol.* 2012;4(1):314-8. (Polish)
10. Bottin R, Marioni G, Rinaldi R, Boninsegna M, Salvadori L, Staffieri A. Deep neck infection: a present-day complication. A retrospective review of 83 cases (1998–2001). *Eur Arch Otorhinolaryngol.* 2003;260:576–9.
11. Wong TY. A nationwide survey of deaths from oral and maxillofacial infections. *J Oral Maxillofac Surg.* 1999 Nov;57(11):1297-9.
12. Teichmann G, Schippers GG, Ruckert A, Hildebrandt G. Czy zębopochodny ropień mózgu jest rzadko spotykanym powikłaniem? *Magazyn Stomat.* 1995;6:39-41. (Polish)